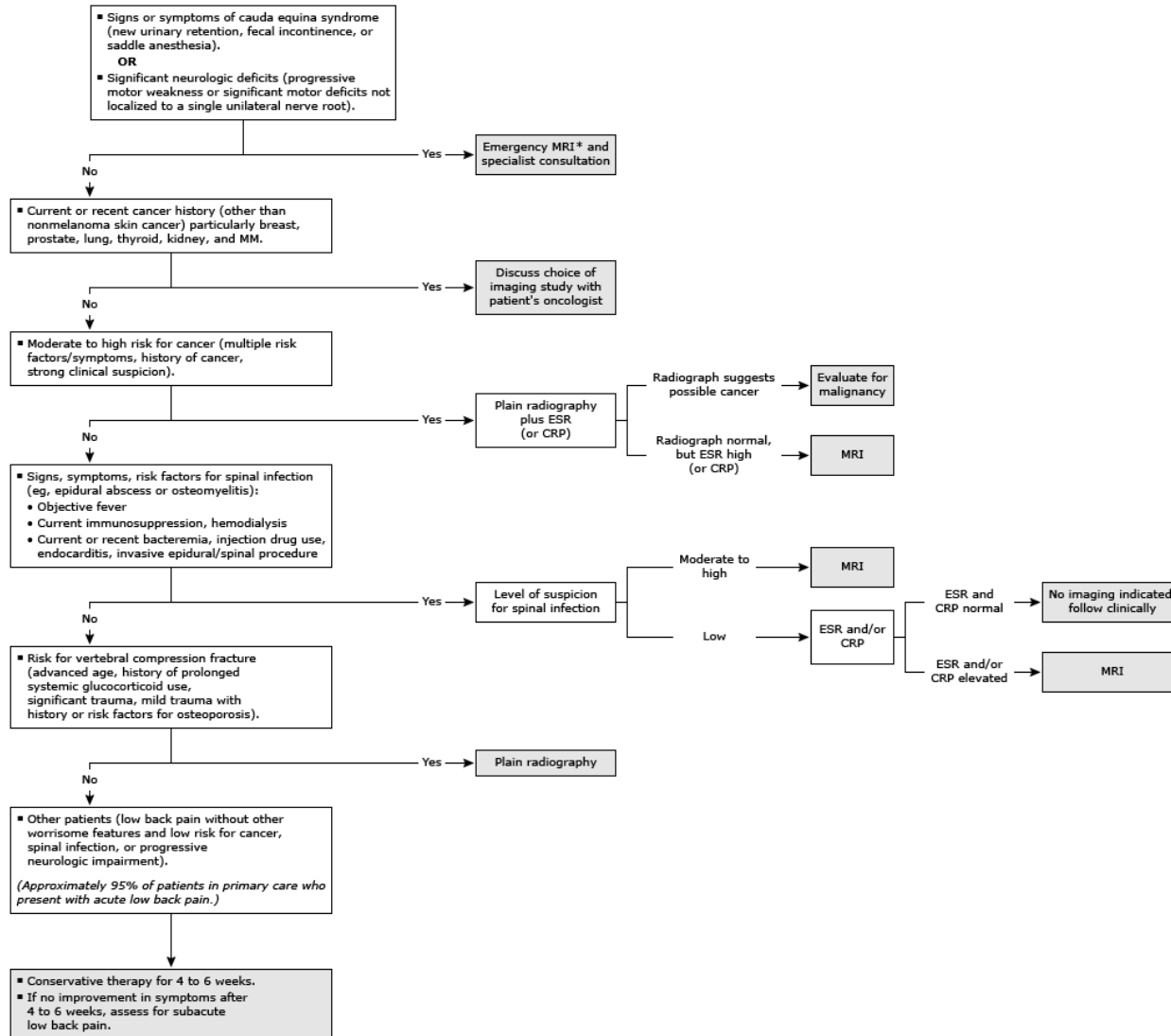


Acute low back pain: Considerations for imaging

This algorithm is intended to assist with the evaluation of patients with acute (<4 to 6 weeks) low back pain in whom imaging is being considered. Most patients (95%) will not require immediate imaging.

Exclusion: History of significant trauma.



MRI: magnetic resonance imaging; MM: multiple myeloma; ESR: erythrocyte sedimentation rate; CRP: C-reactive protein; CT: computed tomography.

* Lumbar spine MRI without contrast is usually appropriate. If there is concern for cancer or infection or if there is history of prior surgery at the site, MRI without and with contrast is recommended. CT with contrast is the alternative exam if MRI is contraindicated.